

2003 ANGLO-GEORGIAN NOKALAKEVI EXPEDITION.

Osteological Assessment for Trench A and B

Benjamin Neil

SUMMARY

The Excavation of 13 burials in trench 'A' and 'B' is reported. In total, 16 individuals were found. 11 individuals were aligned East-West, 4 of which occurred in trench 'A' and 8 in trench 'B'. The remaining 2 individuals in Trench 'A' were aligned North-South, as was the remaining individual in Trench 'B'. Of all the inhumations only 1 individual in trench 'B' was buried in a simple coffin, however many other skeletons showed signs of being in a similar environment. A disarticulated, un-orientated and partial deposit of a single skeleton was found in the North-East extension of trench 'B'.

The integrity of all skeletons had seriously been compromised in situ, thus significant (yet selective) restoration was undertaken in order to extrapolate metric and non-metric data. The study of the skeletal remains from Trench A indicates 1 male, 1 female, 2 juveniles and 1 neonate; Trench B indicates 4 males, 4 females, 1 juvenile and 1 unsexed adolescent.

The following assessment is divided into three parts. The first section will be a description of the grave cuts, with the second section detailing each inhumation within the grave. The third section will be a selective overview of the skeletal material, discussing the sample as a whole. Plans and plates are confined to the appendices.

DESCRIPTION OF THE GRAVES

The following description will detail the shape, size, depth, orientation and truncation of the 13 graves excavated in this 2003 season.

[141] A sub circular, oval poorly defined cut aligned NNE-SSW. Dimensions are 1m in length, 0.43m in width, 0.07m in depth and truncated to the East. Contains skeleton (138).

[143] A linear, arbitrary and poorly defined cut aligned WNW-ESE. Dimensions are 2.42m in length, 0.61m in width, 0.18m in depth and truncated to the North. Contains skeleton (139).

[147] A sub circular, heavily truncated cut. Dimensions are 0.84m in length and 0.67m in width. Contains skeleton (144).

[150] A sub rectangular poorly defined cut aligned WNW-ESE. Dimensions are 2.13m in length, 0.61m in width, 0.08m in depth and truncated to the West and South. Contains skeleton (148).

[153] Contains skeleton (151).

[156] A rounded rectangular cut aligned E-W. Dimensions are 1.69m in length, 0.51m in width, 0.11m in depth with its sides punctuated by stones. Contains skeleton (154).

[302] A rounded rectangular cut aligned ENE-WSW. Dimensions are 1.62m in length, and 0.37m in width with a NW-SE truncation running through the middle. Contains skeleton (300).

[306] A narrow rounded rectangular cut aligned NNE-SSW. Dimensions are 1.65m in length, 0.40m in width, 0.15m in depth. Contains skeleton (304).

[311] A rectangular cut aligned E-W. Minimum dimensions are 1.66m in length, 0.30m in width, 0.28m in depth. Contains skeleton (307).

[314] An E-W aligned cut with indeterminate dimensions. Contains skeleton (312).

[317] An E-W aligned cut with indeterminate dimensions. Contains skeletons (316) and (325).

[320] An E-W aligned cut with indeterminate dimensions. Contains skeleton (319).

[324] An E-W aligned cut with indeterminate dimensions. Contains skeletons (322) and (323).

GRAVE CATALOGUE

Aging, sexing and stature estimation was accomplished using standard osteological techniques based, where applicable on the degree of epiphyseal and cranial suture closure, changes of the pubic symphysis, dental eruption and attrition and the metrically morphological differences of the Os coxae and skull. The following is a description of each inhumation within the grave, detailing:

1. The context number
2. The orientation
3. The skeleton with comments on its sex, age, stature, position, preservation and pathology
4. Any associated artefacts.

Plans and Plates can be referred to in Appendix A and Appendix B and C respectively.

TRENCH 'A'

Skeleton I. (138) *See plan in appendix A.* Juvenile, aged c. 18 months - 2 years old.

A North-South aligned skeleton lying laterally with the head facing East. In partial articulation and poor preservation, it lies flexed at the pelvis and knee. There is a low percentage of bone survival of mainly cranial and shaft fragments, some ribs and vertebrae. The bone is friable but there is no observed trauma or pathology. *See plate A in appendix B.*

Skeleton II. (139) *See plan in appendix A.* Female, aged <17 years old, ht: 150.4cm +/- 4.45cm.

An East-West aligned skeleton, with the head facing East. In full articulation and fair preservation, it lies extended and supine with its right arm flexed at the elbow and hand over the left ribs; the left arm is flexed at elbow to bring the hand over the right side of the pelvis. Considerable in situ fragmentation has occurred, particularly of the of the cranium and shaft bones. Notably, the maxilla lies at the back of the skull. No observed trauma or pathology. *See plate B in appendix B.*

Skeleton III. (144) *See plan in appendix A.* Neonate.

An East-West aligned skeleton, with the head facing West. The diminutive skeletal quantity is disarticulated, fragmented, mottled and in a poor, friable condition. No observed trauma or pathology. *See plate C in appendix B.*

Skeleton IV. (148) *See plan in appendix A.* Male, aged 20-30 years old, ht: 166.13cm +/- 3.27cm

A WNW-ESE aligned skeleton with the head facing ESE. In full articulation and poor preservation, it lies extended and supine. The left arm is flexed at the elbow to bring the hand over the right shoulder; the right arm is flexed at the elbow to bring

the hand over the pelvis. Considerable in situ fragmentation has occurred of all skeletal elements. A spindle whorl and an earring are located by the left hand. Observed pathology: related caries of the LM₁, LM₂ and an un-sided pre-molar. *See plate D in appendix B. See pathology plate A1 in appendix C.*

Associated artefacts: /46

Skeleton V. (151) *See plan in appendix A. Juvenile, aged 8 years old +/- 2 years.*

A North-South skeleton with the head in the North facing East. Its diminutive skeletal quantity is articulated yet very fragmentary. It lies flexed and lying laterally on its left. The left arm is flexed with the hand resting under the skull. Both legs are flexed at the hips and knees with the feet to the South-West. A copper ring rests against the left mandible; around the arm is a copper bracelet (with consequential staining) and beneath the skull are glass beads. No observed trauma or pathology.

See plate E in appendix B, see plate A2 in appendix C.

Associated artefacts: /47\ /48\ /49

Skeleton VI. (154) *See plan in appendix A. Juvenile, aged 10 - 12 years old.*

An East-West aligned skeleton with head in the East facing South-West. In full articulation and poor preservation, it lies flexed and originally lying slightly laterally on its left. In situ decomposition movement sees the skeletal elements supine. The left arm is flexed at the elbow to bring the hand up under the chin, the right arm is flexed at the elbow with the hand resting over the right iliac crest. Both legs are flexed at the hips and knees with the feet to the North. The bone is considerably fragmented, mottled and friable. Around the left arm are 2 bracelets; around the right arm there is 1 bracelet. Many faience and glass beads are around the skull base. No observed trauma or pathology. *See plate F in appendix B.*

Associated artefacts: /51\ /52\ /53\ /54\ /55\ /56\ /57\ /58\ /59

TRENCH 'B'

Skeleton I. (300) *See plan in appendix A. Indeterminate sex, aged <17 years old, indeterminate stature.*

An East-West aligned skeleton, with the head facing East. The diminutive skeletal quantity is in partial articulation and good preservation, it lies extended and supine with the right arm flexed at the elbow to bring the hand up by the left shoulder. It has been truncated by a NW-SE cut, removing the left arm, vertebrae, pelvis and femurs. No observed trauma or pathology.

Skeleton II. (304) *See plan in appendix A. Male, aged 50-55 years old, ht: 169.73cm +/- 4.32cm*

A NNE-SSW aligned skeleton with the head facing SSW. In full articulation and good preservation it lies extended and supine with its right arm flexed at the elbow to bring the hand over the left pelvis. In situ displacement has occurred of the left

ulna, radius, patella and fibula towards the median sagittal plane. The bone is fragmented.

Observed pathology: Osteoporosis of the lumbar and thoracic vertebrae. Caries occur on RM₁ and RM₂ with an abscess resulting from periodontitis around RM₂ alveolar process. Caries also occurs on the 1st right molar of the maxilla. Overall pitting and a lesion occur along left side of the median palatine suture indicating early stages of leprosy. A possible sword trauma runs from the top of the Glabella through the left-hand body of the maxilla; at each end of the cut is a single radiating non-displaced fracture. Possible congenital deformation of the skull as it bulges posteriorly slightly and to the left. *See plate F in appendix B. See pathology plate B1-B5 in appendix C.*

Associated artefacts: /41

Skeleton III. (307) *See plan in appendix A.* Female, aged 48.8 years old +/- 10.5 years, ht: 154.87cm +/- 3.72cm.

An East-West aligned skeleton with the head facing East. In full articulation and fair preservation, it lies extended and supine with both left and right arms flexed at the elbows bringing the hands to rest over the respective clavicles. Legs appear to have been crossed however the distal half of the left tibia is missing. Considerable fragmentation of the bone has occurred.

Observed pathology: Ankylosing spondylitis on lumbar vertebrae and general bone mass reduction. Resorption of mandibular and maxillary molar alveolar bone has occurred. A probable cancerous pathology occurs on the internal plane of the skull, just posterior to the right coronal suture. Sporadic and fine pitting around the supra-orbital ridge and palatine process and general cortical bone thinning of the maxillary body occurs indicating the early stages of leprosy. *See plate G in appendix B. See pathology plate B6-B9 in appendix C.*

Skeleton IV. (312) *See plan in appendix A.* Female, aged 18-24 years old, ht. 155.86cm +/- 3.72cm

An East-West aligned skeleton with the head facing East. In partial articulation and fair preservation, it lies extended and supine with arms, sternum and vertebrae displaced and the left tibia, fibula and foot missing. Bone is in a poor, friable condition with significant markers of root action. No observed trauma or pathology. *See plate H in appendix B, see plate B10 in appendix C.*

Skeleton V. (316) *See in appendix A.* Male, aged approx 35 years old, ht: 169.22cm +/- 3.27cm.

An East-West aligned skeleton, with the head originally facing East. In full articulation and good preservation it lies supine and extended with the left arm flexed at the elbow to bring the hand over the right elbow and the right arm lies to

bring the hand over the pubis. The right leg is flexed medially at the pelvis and knee. The skull has rolled back in situ presenting the skull Norma Basalis.

Observed pathology: Failure of milk molar tooth extraction. LM₁ LM₂ and LP₃ are fully descended, precluding further direct milk tooth attrition. LP₄ is still in a descending state, but at an angle. An abscess has formed resulting in receded alveolar bone, exposing LP₄. Congenital fusion of 2 thoracic vertebrae. *See plate I in appendix B. See pathology plate B11 and B12 in appendix C.*

Skeleton VI. (319) *See plan in appendix A.* Juvenile, aged 6 years old +/- 2 years.

An East-West aligned skeleton, with the head facing South and lying directly over skeleton (325). In partial articulation and poor preservation, it lies extended and supine. Both tibia, fibula and feet are missing, but the position of the femurs indicates the legs would have crossed. The surviving skeletal elements are considerably fragmented. Significant attrition of the milk teeth has occurred. *See plate J in appendix B.*

Skeleton VII. (322) *See plan in appendix A.* Female, aged 33-45 years old, ht. 158.77cm +/- 4.45cm

An East-West aligned skeleton with the head facing North and lying directly over skeleton (323). In articulation and good preservation, it lies extended and supine with the left arm flexed at the elbow to bring the hand over the right elbow. Truncation has occurred though the femurs, removing the majority of the lower appendicular elements. The bone is robust but severely fragmented.

Observed pathology: caries on all molars of the mandible. *See plate K in appendix B. See pathology plate B13 in appendix C.*

Associated artefacts: /60

Skeleton VIII. (323) *See plan in appendix A.* Male, aged >30 years old, indeterminate stature.

An East-West aligned skeleton with the head facing East. In articulation and good preservation, it lies extended and supine with both arms flexed at the elbows and across the abdomen. As with (322) truncation has occurred though the femurs, removing the majority of the lower appendicular elements. The bone is severely fragmented.

Observed trauma and pathology: Significant dental calculus formation on mandibular teeth. Smooth V shaped groove in RM₁. Possible sword trauma to the upper right femur. *See plate L in appendix B. See pathology plate B14 in appendix C.*

Skeleton VIII. (325) *See plan in appendix A.* Female, aged 34.7 years old +/- 7.8 years, ht: 161.55cm +/- 3.72cm

An East-West aligned skeleton in articulation and good preservation. It lies extended and supine with the right arm flexed at the elbow across the abdomen. The bone is severely fragmented.

Observed trauma and pathology: significant markers of occupational stress on left humerus, radius, femur and right tibia. Observed thread notch on left maxillary incisor. Significant markers of root action on the right parietal bone, which is indicative of surface proximity at some point. *See plate M in appendix B. See pathology plate B15-B20 in appendix C.*

Associated artefacts: /61\ /62

Skeleton VX. *Unstratified.* Male, aged 25-30 years.

A disarticulated, un-orientated and partial deposit of a single skeleton in the overburden strip of the North-East extension of trench 'B'.

DISCUSSION

Setting

The settlement of Nokalakevi was constructed on the edge of the Colchian plain on a high ridge beside the River Tekhuri. The acropolis atop the escarpment commands views to the south and east across the plain and northwards into the mountains. Walls running down the mountainside connect it to a lower town enclosed by a loop of the river as it exits the mountains via a narrow gorge. On the east side of the town, successive rulers built three parallel defensive walls with towers and a strongly fortified gate. Several churches, two bath-houses, two 'palaces' and other standing and buried remains of the 4th to 6th century are set within these fortifications.

Cultural and phase indications through orientation and associated artefacts.

Consideration must be taken for the method of how these burials were orientated as well as the reasons. Through the multi-phase nature of the skeletal sample, skeletons were seen to be orientated along every major axis (E-W and N-S).

To illustrate, in trench A, 4 skeletons were orientated E-W and 2 orientated N-S. Of those, 1 N-S and 2 E-W orientated skeletons had associated artefacts. In trench B, 8 skeletons were orientated E-W and 1 orientated N-S. Of those, 1 N-S and 2 E-W orientated skeletons had associated artefacts.

The Christian practice of E-W orientated inhumation is typically seen with an absence of artefact association. However, in this particular case, E-W orientated skeletons with artefacts can be seen as an indication of a cultural and phase transition thus correlating to changing beliefs through time, i.e. from Hellenistic to Christian.

The quality of grave goods has given a good indication of dates for these burials but taking into account the potential production life span of some of the artefacts within the associated burial orientation, estimates are provisional. Thus, finds in Trench 'A' date the current level to the Hellenistic period whereas in Trench 'B', the associated finds possibly date to the 6th century. I refer you to the site report for specific details.

The only physical evidence for a coffin burial was within cut [311], containing skeleton (307). The coffin box (310) only survives partially with the wood being black and very friable, so much so that in most places, it continues only as a soil stain. There was a notable absence of coffin nails, which indicates the possibility of dowel joints and pegs to secure the timber. Other skeletons, notably (312), (316), (322) and (323) bore indications that they had been in coffin environments through natural skeletal movement resulting from decomposition.

Through the nature of this interim report, the following is not a comprehensive or systematic analysis of the skeletal material found at Nokalakevi during the 2003 season. Of the time given during the excavation, the author had 3 weeks to assess 16 skeletons. In Addition to the basic assessment, the physical nature of the inhumations were observed and a number of gross pathologies and traumas identified, some of which are discussed here.

PATHOLOGY

Overview.

The majority of the sample had suffered considerable in situ fragmentation, so significant reconstruction of major skeletal components was conducted in order to extrapolate useful data. At present, there is no catalogue of the individual remaining skeletal components, purely because of time constraints. However, funding permitting one will be made.

Ankylosing spondylitis

There was one observed case of ankylosing spondylitis on skeleton (307). Only 2 of the Lumbar vertebrae were affected, yet the ligament calcification is clear as can be seen in Plate B9 in appendix C.

Cancer

The only (reservedly) deduced neoplasm in this year's sample was on skeleton (307) (*see plate B6 in appendix C*). However, this is not a primary bone tumour, but the result from the interaction with a possible meningioma. Usually found intracranially (as in this case), the average age of an infected person is 45 years old, which correlates in with the metric age estimation for this individual. The tumour is benign and affects surrounding (unaffected) tissue by compression and in this case, erosion. Physically, this tumour would have applied pressure to the primary motor area of the right cerebral hemisphere, thus affecting the voluntary contractions of specific muscle groups on the left hand side of the body.

Dental Caries

There is a noticeable difference between the two areas in regard to the quality of the skeletal dentition. The vast majority of the individuals in Trench B suffered caries habitually, in that they result from excessive mechanical attrition. Molars are disproportionably worn in relation to the other teeth suggesting a gritty diet. Taking this into account, estimations of age from dental attrition are conservative. It is also seen in the sample from Trench B that modification has resulted from direct cultural habits such as the thread notch on left maxillary incisor of skeleton (325) (*see plate B17 in appendix C*) and an unexplained 'v' shaped groove on RM₁ of skeleton (323) (*see plate B14 in appendix C*). In contrast, the quality of the dentition of the sample in Trench A is of a much higher standard. However, it must be noted that the sample is metrically younger than those from trench B thus less time passed for these individuals to affect dental attrition.

Leprosy

There is some uncertainty over the number of individuals having suffered leprosy within this sample. However, the skeletons in question are confined to those in Trench B. Without further analysis, the

observations are provisional, but it seems likely that skeleton (307) did suffer with the early stages of leprosy as indicated by the sporadic and fine pitting around supra-orbital ridge and palatine process and the general cortical bone thinning of maxillary body. Skeleton (304) also displays signs of leprosy with pitting over the palatine process, involving a lesion running along the left side of the median palatine suture.

Markers of Occupational Stress (MOS)

Though the sample was not systematically analysed for MOS, there were obvious examples to be seen. Skeleton (325) from Trench B displayed hypertrophy of the deltoid tuberosity on the left humerus, and the gluteal tuberosity and linea aspera on the femurs of skeleton (*see plate B18, B19 and B20 respectively in appendix C*). The Deltoid Muscle that inserts onto the deltoid tuberosity has multiple actions: the anterior part flexes and medially rotates the arm; the posterior part extends and laterally rotates the arm, whilst the lateral fibres abduct the arm. Hypertrophy of the linea aspera on the femur as indicated by its flattened, 'mesa-like' ridge; the development is indicative of activities that involve direct pull, pressure and compensatory actions of the posterior muscle masses, for example through fishing habits where stabilisation is important. Hypertrophy of the gluteal tuberosity results from the extension and stabilisation of the hip in order to maintain an upright posture under unstable conditions.

Osteoporosis

The only identified case of osteoporosis was with skeleton (304). The collapse of lumbar and thoracic vertebrae with marginal lipping is a characteristic and can be seen in plate B4 in appendix C. Generally, The prevalence of osteoporosis amongst the two sexes is heavily biased towards the female, so it is unusual to see the only observed condition of this year's sample in a male. However, subtler cases may have gone unnoticed.

General state of skeletal sample with taphonomic considerations

The preservation quality of the skeletal material in Trench B is of a much higher standard than those skeletons in Trench A thus reflecting the phase difference between the two areas. However, this also has to be gauged against the mean estimated age between the two trenches, taphonomic and cultural variables. In Trench A the average age is much lower (mean=10 years old) than in Trench B (mean=31 years old), which indicates that the former sample had a higher infant mortality rate than those skeletons in Trench B.

The soil of the region is a dark, sandy clay colluvial deposit with a high clastic limestone content, a natural inclusion, which would aid the process of fragmentation of the skeletal material as the graves became more compacted. Notably there is also a speckling of limestone mortar, which would buffer the acidity of the clay soil. In relation to the preservation of the skeletal material, its degradation would have been faster if this particulate limestone was absent.

In Trench 'A', the collapse of the fortification wall immediately to the East of these burials would have had a significant impact on the skeletal integrity with less than a metre of earth between the two. In Trench 'B' however, there are many possible reasons why skeletal fragmentation occurred. Certainly there is evidence of root action on some of the skeletal elements, which not only compromises the bone structure through the ingress of saprophytic fungi, (which demineralises the bone, making it brittle) it is also indicative of either a shallow interment or at some point the possibility of earthworks and consequential land reduction. Certainly during the Soviet period clearance of the cemetery further south of Trench 'B' occurred. In whichever case, there would have at some time been intense activity over the burial ground for the skeletal material to be in the condition it is now.

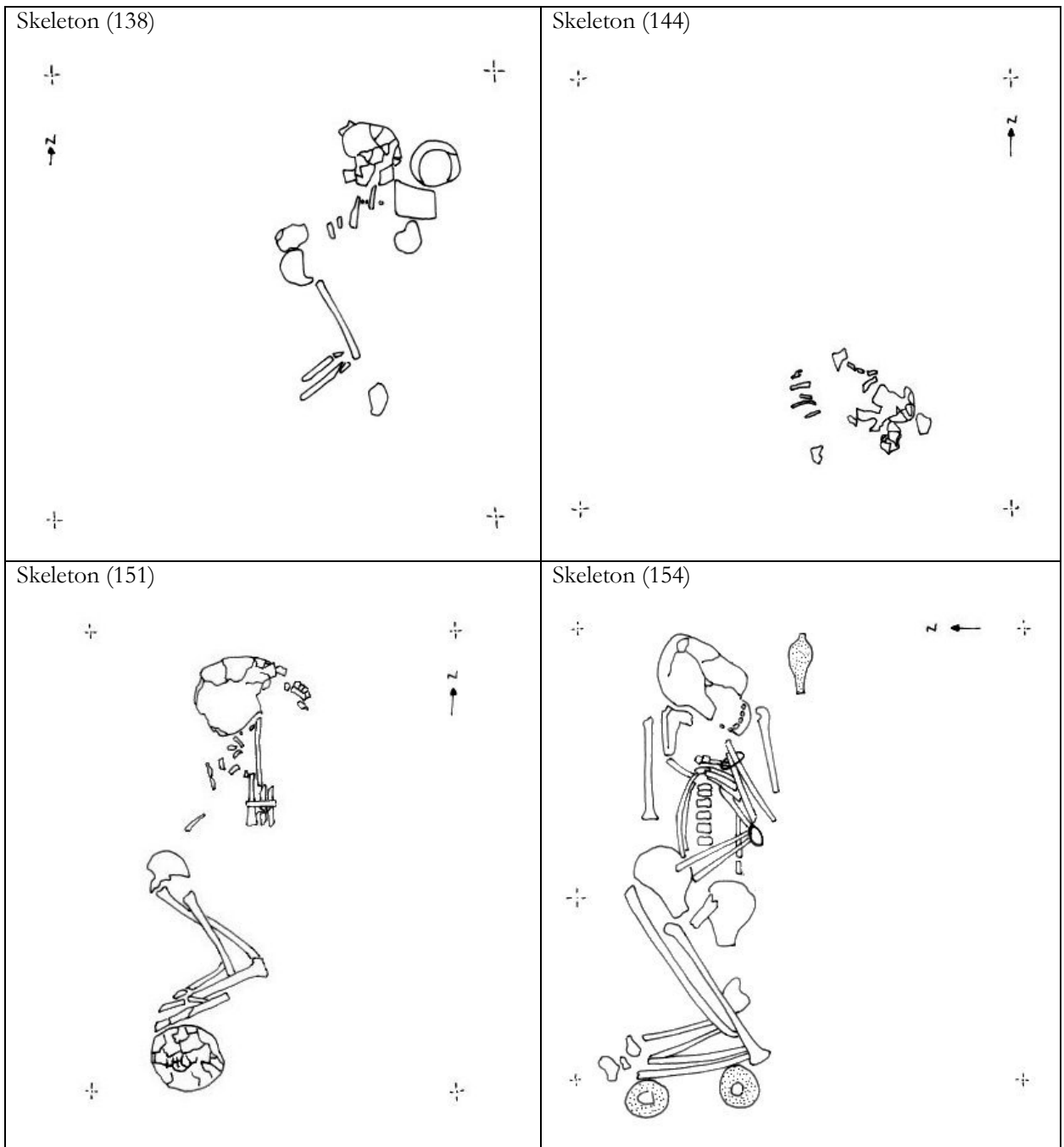
Fungal decomposition is limited however by a number of conditions. One is water, which has a stabilising effect on temperature and pH; this will consequently inhibit both microbial and fungal action. It is an important consideration because metrologically, Nokalakevi is prone to rain due to the hilly nature of the immediate region. Soil porosity however is another important factor in the state of preservation and it was noted that the grave fill was more aerated than the surrounding matrix, which would have enabled greater levels of oxidation of the tissue and skeletal material.

BIBLIOGRAPHY AND FURTHER READING.

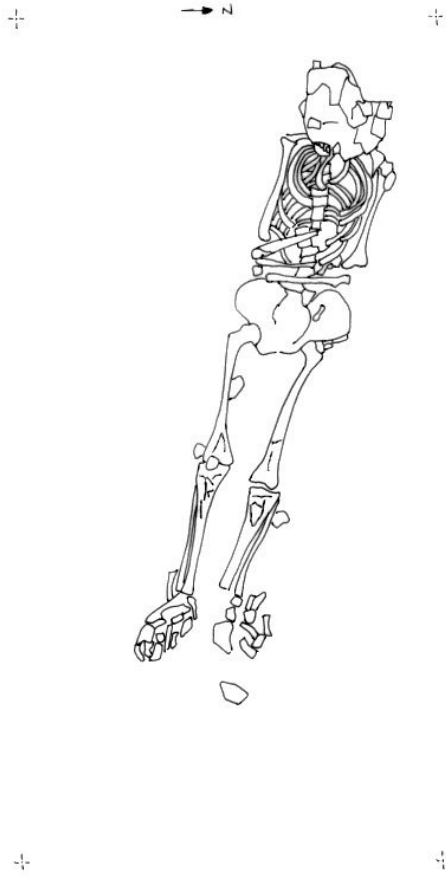- Aufderheide, A., Rodriguez-Martin, C., 1988, *Human Paleopathology*, Cambridge University Press.
- Bass, W.M., 1995, *Human Osteology; A laboratory and field manual*, Columbia, Missouri Archaeological Society.
- Capasso, L. *et al*, 1998, *Atlas of occupational markers on human remains*, Journal of Paleopathology: Monographic publications, Edigrafital, Teramo.
- Child, A., 1995, *Towards an Understanding of the Microbial Decomposition of Archaeological Bone in the Burial Environment*, in Journal of Archaeological Science, 22: 165-174, London, Academic Press Limited.
- Gill-King, H., 1997, *Chemical and ultrastructural aspects of decomposition in Forensic Taphonomy the postmortem fate of human remains*, Haglund, W., & Sorg, M., (Eds) CRC Press, London.
- Grupe, G., & Dreses-werringloer, U., 1993, *Decomposition Phenomena in Thin Sections of Excavated Human Bones*, in Grupe, G., & Garland, A., 1993, *Histology of Ancient Human Bone: Methods and Diagnosis*, proceedings of the 'Palaeohistology Workshop' held from 3 - 5 October 1990 at Göttingen, London, Springer-Verlag.
- Henderson, J., 1987, *Factors determining the state of preservation of human remains in Death, Decay and Reconstruction*, Boddington, A., et al (Eds.) Manchester University Press, Manchester.
- Mays, S., 1998, *The Archaeology of Human Bones*, London, Routledge.
- Piepenbrink, H., 1986, *Two examples of biogenous dead bone decomposition and their consequences for taphonomic interpretation* in Journal of Archaeological Sciences, 13: 417-430, London, Academic Press Limited.
- Rodriguez, W., 1997, *Decomposition of buried and submerged bodies in Forensic Taphonomy the postmortem fate of human remains*, Haglund, W., & Sorg, M., (Eds) CRC Press, London.
- Tortora, G., & Grabowski, S., 1996, *Principles of Anatomy and Physiology*, Harlow, England, HarperCollins.
- White, T., 2000, *Human Osteology*, Academic Press.

APPENDICES

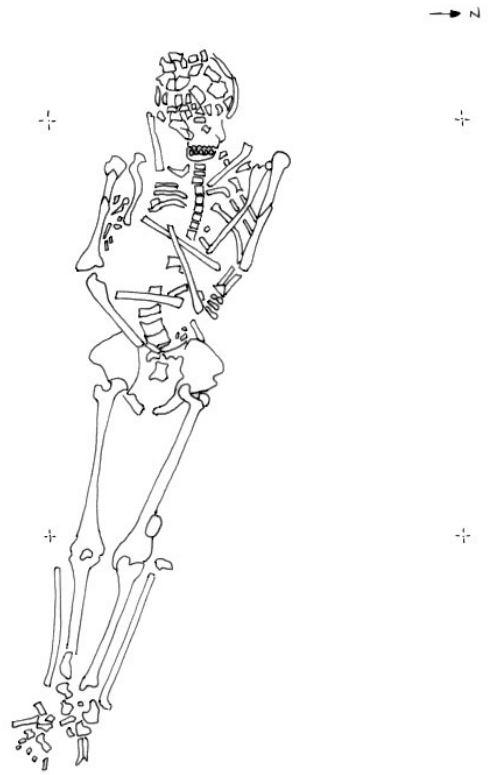
A: Plans



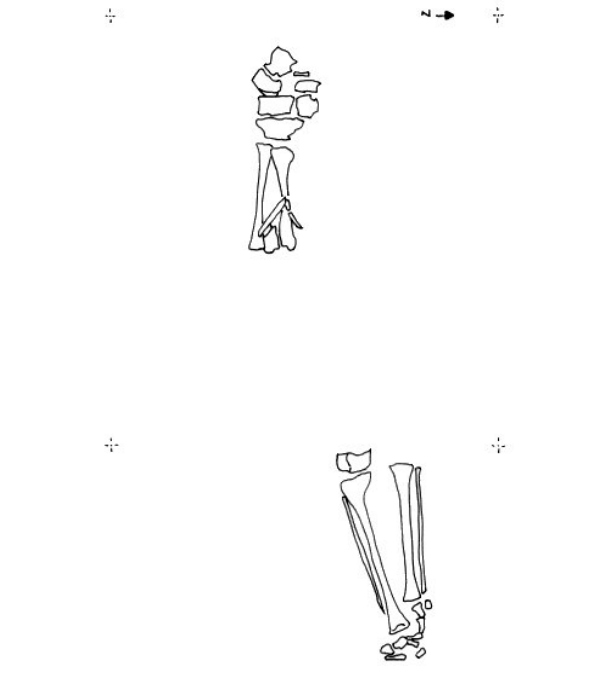
Skeleton (139)



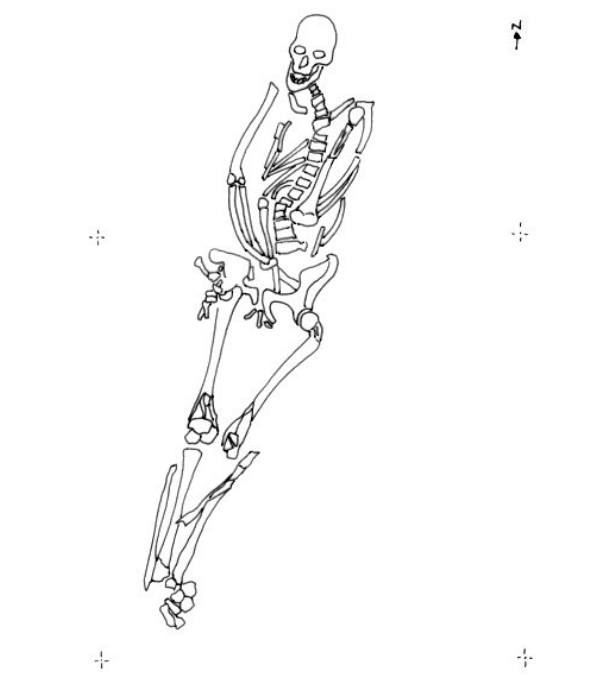
Skeleton (148)



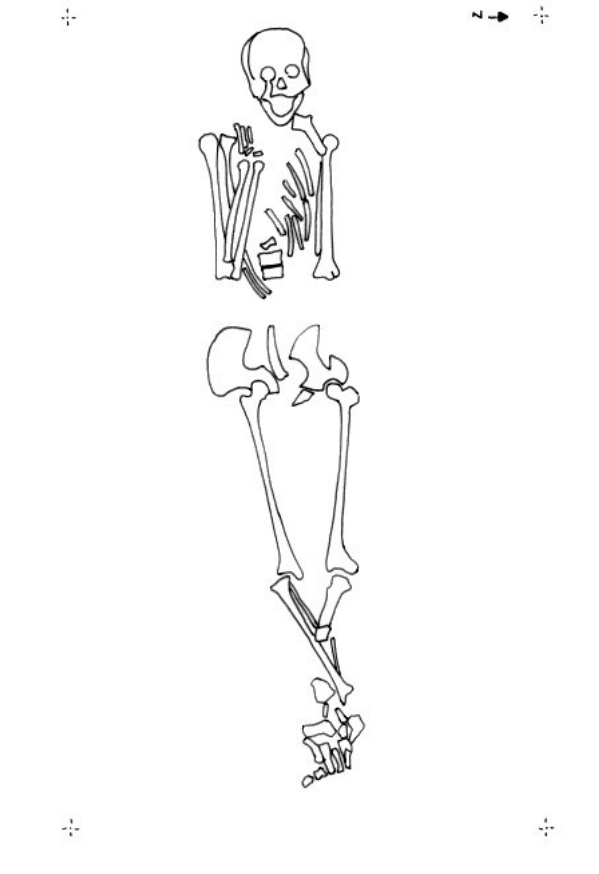
Skeleton (300)



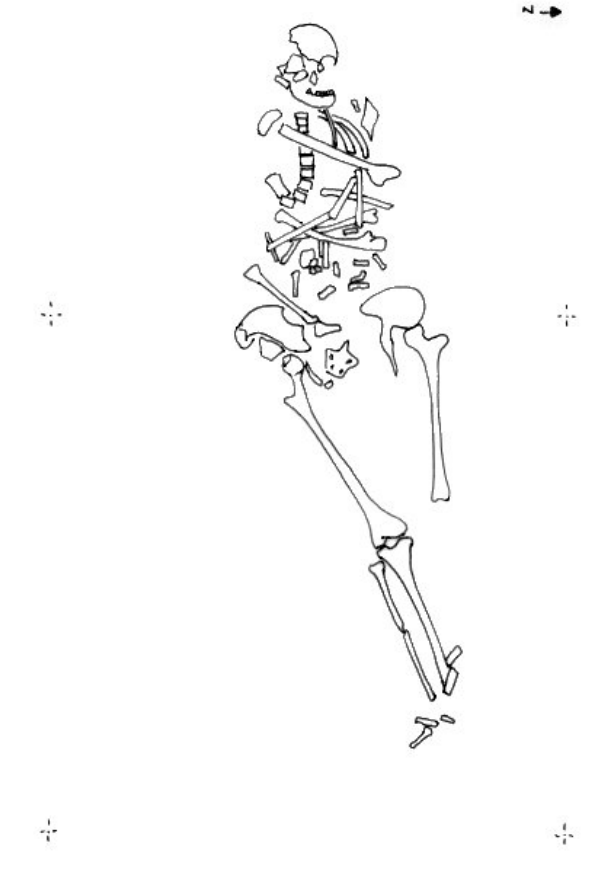
Skeleton (304)



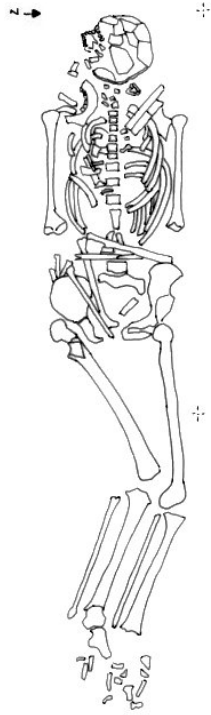
Skeleton (307)



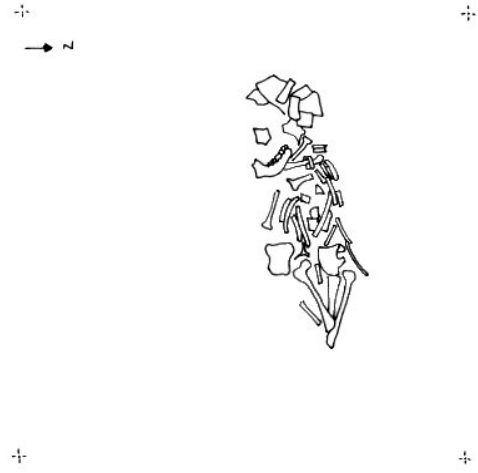
Skeleton (312)



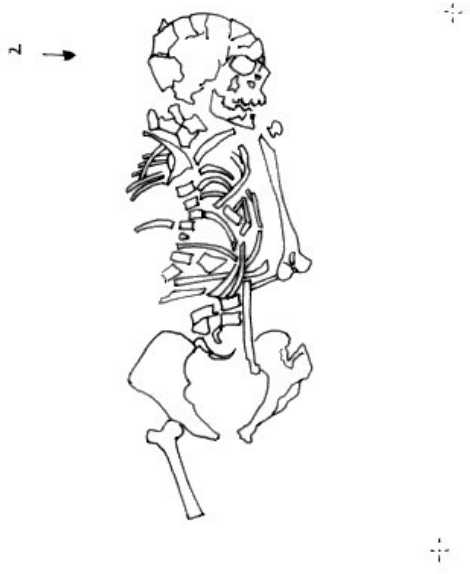Skeleton (316)



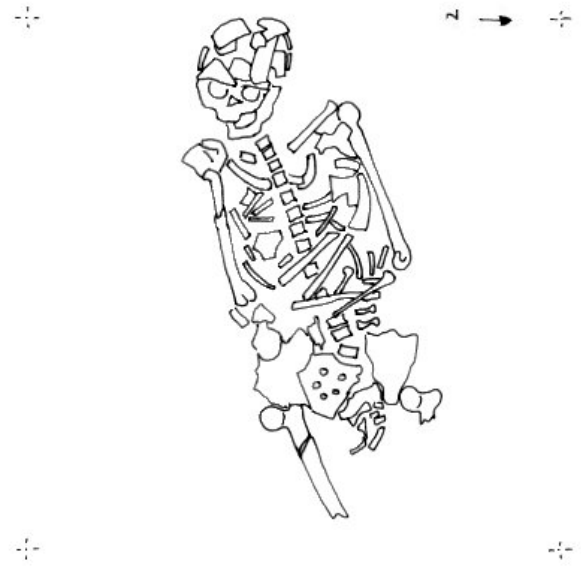Skeleton (319)



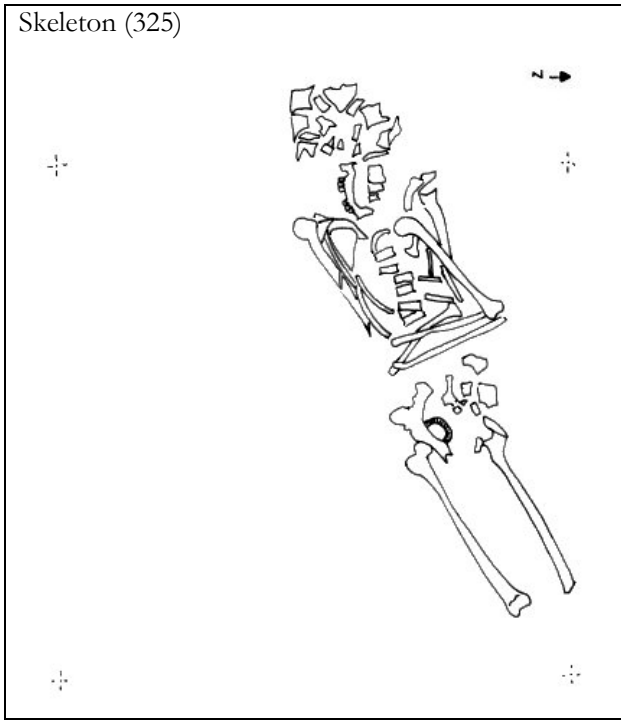
Skeleton (322)



Skeleton (323)



Skeleton (325)



B: PLATES

TRENCH A

Plate A *skeleton (138)*



Plate B *skeleton (139)*



Plate C *skeleton (144)*



Plate D *skeleton (148)*



Plate E *skeleton (151)*



Plate F *skeleton (154)*



TRENCH B

Plate F *skeleton (304)*



Plate G *skeleton (307)*



Plate H *skeleton (312)*



Plate I *skeleton (316)*



Plate J *skeleton (319)*



Plate K *skeleton (322)*



Plate L *skeleton (323)*



Plate M *skeleton (325)*



C: Pathology, Trauma and other Plates

Plate A1: *sk: (148) mandible*

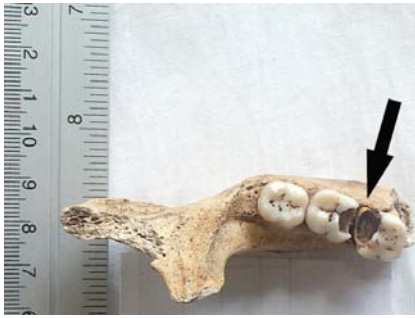

Plate A2: *sk: (151)*



Plate B1: *sk: (304)*



Plate B2: *sk: (304) maxilla*

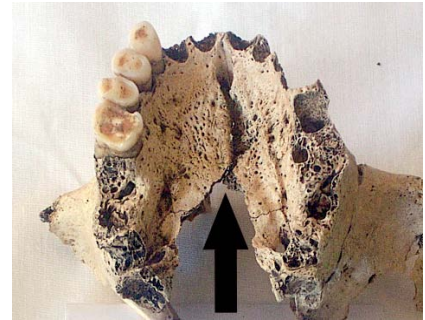

Plate B3: *sk: (304) maxilla*

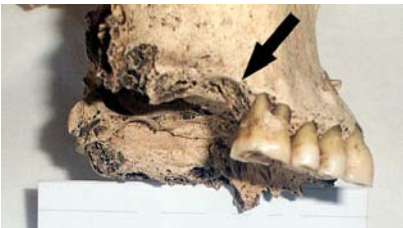

Plate B4: *sk: (304) vertebrae*



Plate B5: *sk: (304) cranium*

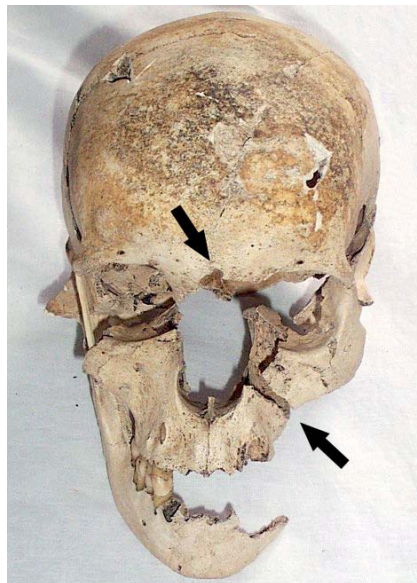


Plate B6: *sk: (307)*

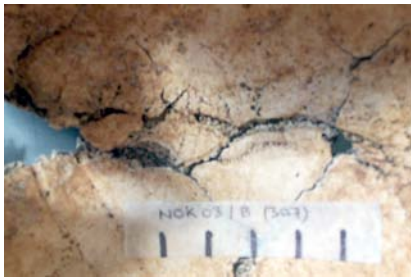


Plate B7: *sk: (307) maxilla*

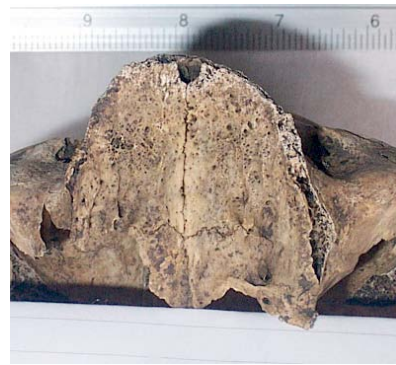

Plate B8: *sk: (307) mandible*



Plate B9: *sk: (307) vertebrae*

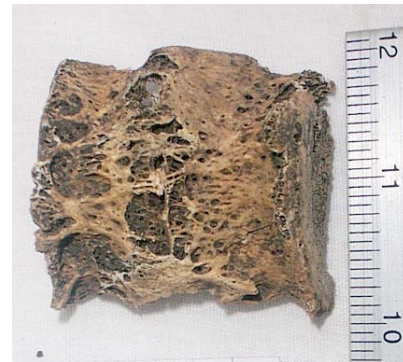

Plate B10: *sk: (312) right femur*



Plate B11: *sk: (316) maxilla*



Plate B12: *sk: (316) vertebrae*



Plate B13: *sk: (322) mandible*

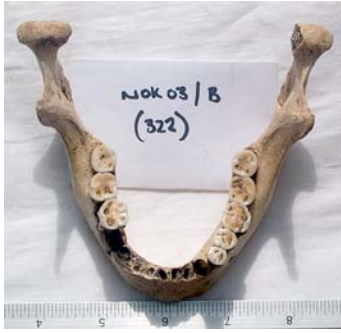

Plate B14: *sk: (323) mandible*

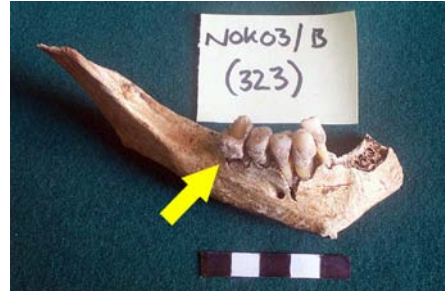

Plate B15: *sk: (325) right parietal bone*

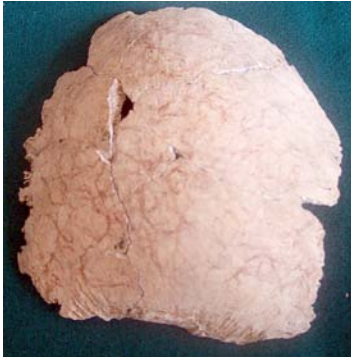

Plate B16: *sk: (325) mandible*

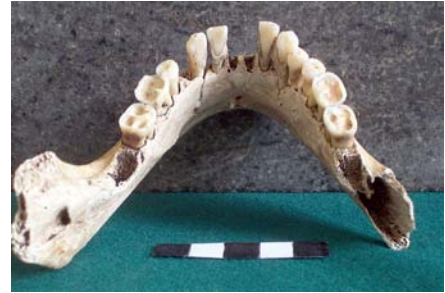

Plate B17: *sk: (325) LI'*



Plate B18: *sk: (325) Humerus*



Plate B19: *sk:(325) prox Humerus*

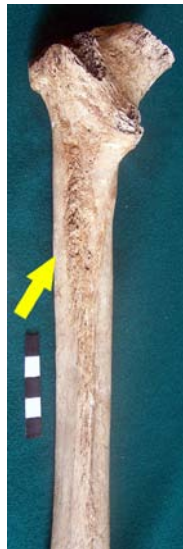

Plate B20: *sk:(325) distal Humerus*

